

Case Report

A case of moyamoya disease in a patient with multi-drug resistant tuberculosis

Kedar M. Tilak*, Sandhya V. Haribhakta

Department of Pediatrics, PGI-YCM Hospital, Pune, Maharashtra, India

Received: 09 July 2019

Revised: 18 July 2019

Accepted: 29 July 2019

*Correspondence:

Dr. Kedar M. Tilak,

E-mail: kedartilak28@gmail.com

Copyright: © the author(s), publisher and licensee Medip Academy. This is an open-access article distributed under the terms of the Creative Commons Attribution Non-Commercial License, which permits unrestricted non-commercial use, distribution, and reproduction in any medium, provided the original work is properly cited.

ABSTRACT

Moyamoya cerebral angiopathy is characterized by progressive stenosis or occlusion of the internal carotid artery or its branches with subsequent development of basilar collaterals. It is commonly seen in Asian population. Authors present a case report of a 12 year-old boy with Multidrug resistant tuberculosis with Moyamoya disease. Moyamoya disease rarely coexists with tuberculosis. However, we can infer that tuberculosis may coexist in a patient in a patient of Moyamoya disease.

Keywords: Angiography, Moyamoya disease, Tuberculosis, Vasculitis

INTRODUCTION

Takeuchi and Shimizu first described this type of angiopathy in 1957 in Japan that was later on called Moyamoya disease (MMD) in 1969.^{1,2} The term Moyamoya in Japanese language means a puff of smoke and the disease was so named due to its similar appearance on angiography. The cerebral angiopathy is characterized by progressive stenosis or occlusion of the internal carotid artery or its branches with subsequent development of basilar collaterals.³ Moyamoya disease (MMD) refers to isolated and primary moyamoya angiopathy, which is usually bilateral. Moyamoya syndromes (MMS) correspond to moyamoya angiopathy that occurs unilaterally or is associated with other neurological with or without a well-known associated congenital or acquired condition.⁴ The pathophysiology of Moyamoya disease remains unknown and many studies are being undertaken to find out more about it. Irrespective of the cause, Moyamoya angiopathy increases the risk of ischemic and hemorrhagic brain

damage. Moyamoya disease and pulmonary tuberculosis rarely occur together in the same patient. In this case report, we have described a rare case of Moyamoya disease coexisting with Multidrug resistant Pulmonary Tuberculosis in a twelve-year-old patient. After reviewing the available literature, we came across only one reported case of Moyamoya disease coexisting in a patient with pulmonary tuberculosis in an adult patient.⁵

CASE REPORT

Authors present a case of a 12-year-old Asian boy who came to the hospital with complaints of continuous fever. The patient had fever since four weeks with a reported temperature in the range of 100-102.5 F. There was an evening rise in temperature associated with profuse sweating. The fever was associated with chills. The parents gave a history of seven kilos (15.43lbs) weight loss over a period of one month. He also had productive cough since four weeks. There was no history of hemoptysis. The relatives of the patient also gave a

history of a right sided hemiplegia that developed in the patient about a year back for which the patient did not seek any medical attention. Other medical histories were unremarkable. Also, the patient denied any contact or exposure to a patient with Active Tuberculosis.

On clinical examination, the patient looked moderately well, but had an emaciated appearance (BMI= 12.4). However, he was in no significant distress. The patient had a body temperature of 100 F, pulse rate of 100beats/min, respiratory rate of 30cycles/min and a blood pressure of 100/70 mm Hg. On examination of the Chest, the patient had bilateral coarse crepitation with decreased air entry in the right lung.

Blood investigations revealed a hemoglobin level of 8.5 g/dL, a total leukocyte count of 11,260/mm³ (79.7% neutrophils, 11.2% lymphocytes) and an adequate platelet count. The Erythrocyte sedimentation rate was 65 mm/hour. Blood chemistry, liver profile, renal profile and other coagulation studies were found to be within normal limits. Chest X-ray showed an opacity at the base of the right lung in the lower lobe suggesting active infection (Figure 1). Tuberculin skin testing showed an induration of 20 mm * 18 mm. Sputum was positive for Acid Fast Bacilli (AFB) and the CBNAAT (Genexpert) testing was positive for active tuberculosis infection. Human immunodeficiency virus (HIV) enzyme-linked immunosorbent testing was negative.

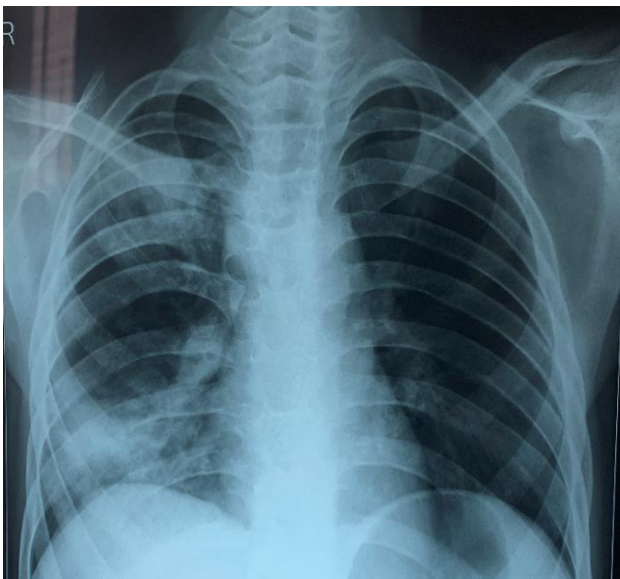


Figure 1: Patch in the right lower lobe.

The GeneXpert testing also concluded that the infectious organism was resistant to the first line drugs Isoniazid and Rifampicin, which are used to treat Tuberculosis infections. Therefore, the standard tuberculosis treatment with first line agents could not be started for the patient. He had to be started on the Multi-drug resistant Tuberculosis regimen with drugs like amikacin,

moxifloxacin, pyrazinamide, ethambutol and PAS. In spite of resistance, isoniazid was continued.

The patient had a history of right-sided hemiplegia with residual weakness. So, we did a complete neurological examination with imaging. The patient had no episodes of loss of consciousness and seizures. He was alert, active and oriented to time, place and person. The sensory system examination was normal. On examining the motor system, he had decreased power on the right side (Grade 3/5) as compared to the left side (Grade 5/5). The cranial nerves were normal on testing. We also did a Lumbar puncture, which showed normal values and pressures. Gram and Zeihl-Neelsen (ZN stains) were negative. The electroencephalogram (EEG) was normal. Magnetic resonance angiography (MRA) showed a picture, which was consistent with Moyamoya disease. Figure 2 shows a typical puff of smoke appearance due to branching collaterals.

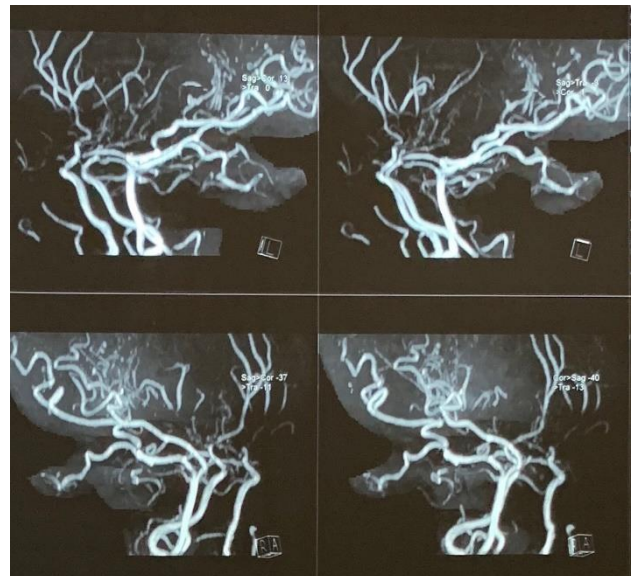

Figure 2: Collaterals on MRA.

DISCUSSION

The clinical features of Moyamoya disease are because of changes in the blood flow due to the stenosis of the Internal Carotid artery and its branches. Moyamoya disease can have variable presentations depending on the demographic characteristics of the population under study. The disease usually shows a bimodal peak with children around 5 years of age and adults in their mid-40s.⁶ Also, the disease is likely to affect females twice as likely as males.⁷ In most cases, the patients present with symptoms of ischemia (transient ischemic attacks (TIAs), strokes and seizures) and a few of them present with a history of intracranial hemorrhage. Moyamoya disease is relatively rare outside Asia.⁸

In most of the Asian population, the children primarily suffer from ischemic symptoms and adults experience

intracranial hemorrhage. In our case, the patient presented with a history of hemiplegia with residual weakness.⁹

To talk about the genetics of Moyamoya disease, most of the familial cases are polygenic or are inherited in an autosomal dominant pattern with incomplete penetrance.^{5,10} Along with this, increased levels of many growth factors, enzymes and peptides have been linked with Moyamoya disease.¹¹ Therefore, the disease was presumed to be hereditary and multifactorial.¹² The characteristic histopathology seen in Moyamoya vasculopathy shows a thickened intima with smooth muscle proliferation with tortuous duplicated internal elastic lamina.¹³

The differential diagnosis in a stroke patient of the pediatric age group is large. Acute Ischemic Stroke (AIS) is by far the most common cause of pediatric stroke. Cardiac disease is the most common cause of stroke in childhood, accounting for up to a third of all AIS.^{14,15} The other common causes include hematological diseases like sickle cell disease and prothrombotic disorders, infections like varicella, HIV and TB, Vascular causes like arteriovenous malformations, vasculitis, malignancy, trauma, drugs and also syndromic causes like Marfan syndrome and homocystinuria.¹⁴ Many diseases may be associated with Moyamoya syndrome, which include Grave's disease, Fanconi anemia, sickle cell anemia, fibromuscular dysplasia, lupus anticoagulant disease, Down's syndrome, Marfan syndrome, Turner's syndrome, von Recklinghausen disease, Hirschsprung disease, aplastic anemia, coarctation of the aorta, leptospirosis, HIV, TB, cranial trauma, radiation injury, parasellar tumor and hypertension.^{5,16,17-20}

After observing the autopsy findings in cases of tuberculous meningitis, it was repeatedly stressed that arteritis is the cause of narrowing and occlusion of the cerebral arteries which was seen on angiography¹⁶. Also, cerebral arteritis in association with tuberculosis apart from the nervous system has been reported by some authors.^{21,22} In our case, the patient had a history of hemiplegia one year back for which he did not seek any form of treatment. Also, the development of resistance to first-line anti-tubercular drugs may be associated with lack of early diagnosis and treatment in our patient. Therefore, after careful review of our patient's clinical history and relevant literature we hypothesize that cerebral arteritis was responsible for the angiographic changes in our patient.

Authors found a few cases of tuberculous meningitis associated with Moyamoya syndrome that have been reported but authors only found one reported case report about a patient who had pulmonary tuberculosis with Moyamoya disease.⁵ Authors also came across only two patients diagnosed with Moyamoya syndrome associated with pulmonary tuberculosis, who were enrolled in a study.²⁴ Therefore, authors can say that the coexistence of

pulmonary tuberculosis and typical Moyamoya syndrome is very rare.^{16,23}

CONCLUSION

There hasn't been any effective treatment determined to treat pulmonary tuberculosis-associated with Moyamoya syndrome, as it is a very rare combination of diseases. Our patient is currently receiving treatment for the Multidrug resistant tuberculosis along with aspirin therapy for the hemiplegic episode.

Funding: No funding sources

Conflict of interest: None declared

Ethical approval: Not Required

REFERENCES

1. Takeuchi K, Shimizu K. Hypoplasia of the bilateral internal carotid arteries. *Brain Nerve.* 1957;9:37-43.
2. Suzuki J, Takaku A. Cerebrovascular moyamoya disease. Disease showing abnormal net-like vessels in base of brain. *Arch Neurol.* 1969;20(3):288-99.
3. Suzuki J, Kodama N. Moyamoya disease - a review. *Stroke.* 1983;14(1):104-9.
4. Guey S, Tournier-Lasserre E, Hervé D, Kossorotoff M. Moyamoya disease and syndromes: from genetics to clinical management. *The Application of Clin Genetics J.* 2015;49-68.
5. Khan FY, Kamal H, Musa R, Hayati A. Moyamoya syndrome in a known case of pulmonary tuberculosis. *J Neurosci Rural Pract.* 2010;1(2):105-108.
6. Baba T, Houkin K, Kuroda S. Novel epidemiological features of Moyamoya disease. *J Neurol Neurosurg Psychiatry.* 2008;79(8):900-4.
7. Nagaraja D, Verma A, Taly AB. Cerebrovascular disease in children. *Acta Neurol Scand.* 1994;90: 251-55.
8. Starke RM, Komotar RJ, Hickman ZL, Paz YE, Pugliese AG, Otten ML, et al. Clinical features, surgical treatment, and long-term outcome in adult patients with moyamoya disease: Clinical article. *J Neurosurg.* 2009;111(5):936-42.
9. Ikezaki K, Han DH, Kawano T, Kinukawa N, Fukui M. A clinical comparison of definite moyamoya disease between South Korea and Japan. *Stroke.* 1997;28(12):2513-7.
10. Mineharu Y, Takenaka K, Yamakawa H, Inoue K, Ikeda H, Kikuta KI, et al. Inheritance pattern of familial moyamoya disease: Autosomal dominant mode and genomic imprinting. *J Neurol Neurosurg Psychiatry.* 2006;77(9):1025-9.
11. Lim M, Cheshier S, Steinberg GK. New vessel formation in the central nervous system during tumor growth, vascular malformations, and Moyamoya. *Curr Neurovasc Res.* 2006;3(3):237-45.
12. Yamauchi T, Houkin k, Tada M, Abe H. Familial occurrence of Moyamoya disease. *Clin Neurol Neurosurg.* 1997; 99(2): S162-7.

13. Fukui M, Kono S, Sueishi K, Ikezaki K. Moyamoya disease. *Neuropathol.* 2000;20:S61-4
14. Tsze DS, Valente JH. Pediatric stroke: a review. *Emerg Med Int.* 2011;2011.
15. Riela AR, Roach ES. Etiology of stroke in children. *J Child Neurol.* 1993;8(3):201-20.
16. Mathew NT, Abraham J, Chandy J. Cerebral angiographic features in tuberculous meningitis. *Neurol.* 1970;20(10):1015-23.
17. Pavlakis SG, Verlander PC, Gould RJ, Strimling BC, Auerbach AD. Fanconi anemia and moyamoya: Evidence for an association. *Neurol.* 1995;45(5):998-1000.
18. Hernández CH, Huete LI, Concha GM, Méndez CJ, Sánchez DN, Cuéllar GM, et al. Moyamoya disease in a girl with Down syndrome: Report of one case. *Rev Med Chil.* 2009;137:1066-70.
19. Jeong HC, Kim YJ, Yoon W, Joo SP, Lee SS, Park YW. Moyamoya syndrome associated with systemic lupus erythematosus. *Lupus.* 2008;17:679-82.
20. Sharfstein SR, Ahmed S, Islam MQ, Najjar MI, Ratushny V. Case of moyamoya disease in a patient with advanced acquired immunodeficiency syndrome. *J Stroke Cerebrovasc Dis.* 2007;16(6):268-72.
21. Iden DL, Rogers RS, Schroeter AL. Papulonecrotic tuberculoid secondary to *Mycobacterium bovis*. *Arch Dermatol.* 1978;114(4):564-6.
22. Rostami M, Emami Z. A case of temporal arteritis due to oral cavity lesion of tuberculosis. *J Res Med Sci.* 2004;2:99-101.
23. Lehrer H. The angiographic triad in tuberculous meningitis. *Radiol.* 1966;87(5):829-35.
24. Peerless SJ. Risk factors of moyamoya disease in Canada and the USA. *Clin Neurol Neurosurg.* 1997;99:S45-8.

Cite this article as: Tilak KM, Haribhakta SV. A case of moyamoya disease in a patient with multi-drug resistant tuberculosis. *Int J Contemp Pediatr* 2019;6:2215-8.