

## Case Report

# Severe haemoptysis in a 5 year old child with Kartagener's syndrome: case report

Mohinish S.\*, Mallesh K., Prashanth H. K., Ravichandra K. R.

Department of Pediatrics, Bangalore Medical College and Research Institute, Bangalore, Karnataka, India

**Received:** 08 November 2019

**Revised:** 27 November 2019

**Accepted:** 02 December 2019

### \*Correspondence:

Dr. Mohinish S.,

E-mail: monishpaeds@gmail.com

**Copyright:** © the author(s), publisher and licensee Medip Academy. This is an open-access article distributed under the terms of the Creative Commons Attribution Non-Commercial License, which permits unrestricted non-commercial use, distribution, and reproduction in any medium, provided the original work is properly cited.

### ABSTRACT

Kartagener's syndrome, a rare autosomal recessive disorder is a type of Primary Ciliary Dyskinesia (PCD) associated situs inversus, bronchiectasis, sinusitis and male infertility. We present a case of a 5-year-old girl who came with features of bilateral glue ear, recurrent sinusitis, recurrent haemoptysis and dextrocardia. She was diagnosed to have Kartagener's syndrome and was evaluated for recurrent haemoptysis.

**Keywords:** Absent bronchus, Dextrocardia, Haemoptysis, Kartagener's syndrome, Primary ciliary dyskinesia, Short neck

### INTRODUCTION

Kartagener's Syndrome (KS) is a ciliopathic, autosomal recessive disorder that causes a defect in the action of the cilia lining the respiratory tract and fallopian tube. It is characterized by a triad of situs inversus of the viscera, sinusitis, bronchiectasis, and ciliary dysfunction. It is also known as Afzelius syndrome, Kartagener's triad, Zivert's syndrome, or Zivert-Kartagener triad.<sup>1</sup> Manes Kartagener first recognized this clinical triad as a distinct congenital syndrome in 1933.<sup>2</sup> As Kartagener described this syndrome in detail, it bears his name.

Males and females are affected equally. The complete syndrome has high familial evidence appearing only in one generation and multiple siblings may have various combinations of its components which do not appear in their children. This disorder affects the activity of proteins important to the movement of cilia especially in the respiratory tract and the spermatozoa leading to defective clearance of mucus and resulting in recurrent respiratory tract infections occasionally progressing to lung abscesses, anosmia, and sterility. It has been

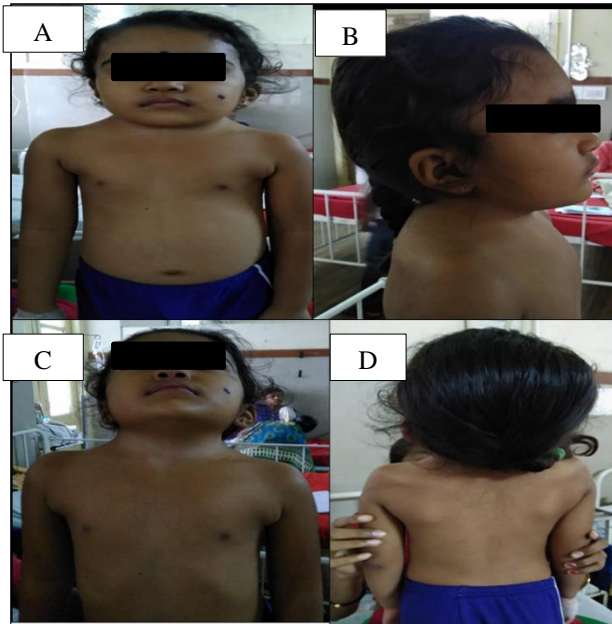suggested that Kartagener's syndrome be listed as a subset of a broader category of diseases called as the immotile cilia syndrome.

### CASE REPORT

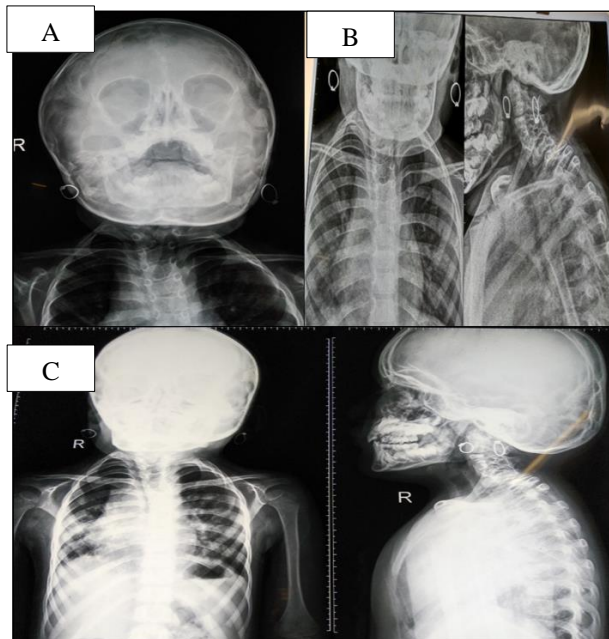
A 5-year-old girl presented to paediatric OPD with history of failure to thrive, recurrent episodes of cough with sputum production, haemoptysis for past 5 month's duration. The nasal discharge was thick, mucoid type. On examination, noted having short stature, short neck, koilonychia, clubbing and severe pallor (Figure 1).

Significant past history of recurrent episodes of cough and cold noted and she was evaluated and was referred here for blood transfusion and expert opinion.

A haematological investigation shows Haemoglobin-5.4 gm% (anaemia), normal total counts, platelets. Coagulation study normal. Peripheral smear shows dimorphic anaemia. TB workup like ESR, Mantoux, sputum AFB, and CBNATT were negative.



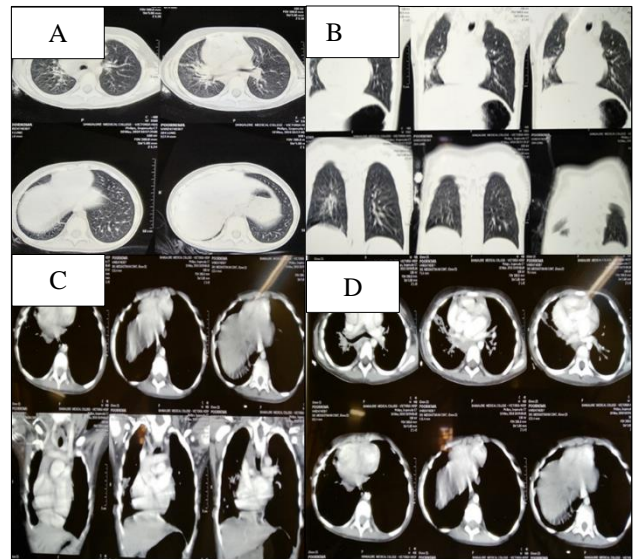
**Figure 1:** (A) Front view, (B) side view, (C) extension neck and (D) back view of the patient. Shows short stature, short neck.



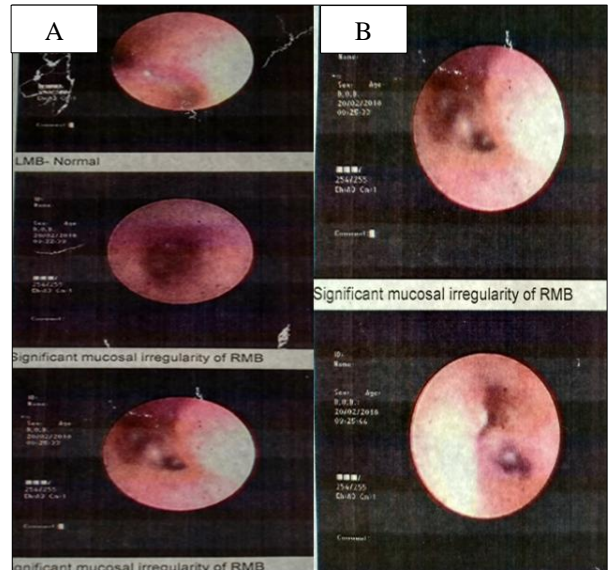
**Figure 2:** (A) Fusion and upper three cervical vertebra noted with loss of cervical lordosis leading to short neck. (B) Mild scoliosis of thoracic vertebra to left side. (C) Chest X ray revealed dextrocardia. Evidence of multiple rings like radio opacities with surroundings fibrotic changes in right mid, lower zone and left mid.

X-ray neck shows fusion and upper 3 cervical vertebra noted with loss of cervical lordosis leading to short neck. Mild scoliosis of thoracic vertebra to left side (Figure 2). Chest X-ray revealed dextrocardia. Also evidence of multiple rings like radio opacities with surrounding

fibrotic changes in right mid, lower zone and left mid zone. Features suggestive of Kartagener syndrome. USG abdomen shows right sided ectopic kidney. 2D echo shows CHD ASD, non-competence LV and Dextrocardia.



**Figure 3:** (A) CT chest shows dextrocardia and (B) right para tracheal, tracheobronchial lymphadenopathy. (C) Patchy consolidation with atelectasis, (D) Bronchiectasis, at right middle lobe, lower lobe.



**Figure 4:** (A) Bronchoscopy under sedation showed absent right upper lobe bronchus. (B) Mucosal irregularity of right middle bronchus (vascular).

CT chest shows dextrocardia and right Para tracheal, tracheobronchial lymphadenopathy. Patchy consolidation with atelectasis, bronchiectasis at right middle lobe, lower lobe (Figure 3). Karyotyping reveals normal 46 XX. With all these clinical and radiological findings a diagnosis of Kartagener's syndrome was made.

Bronchoscopy under sedation showed absent Right upper lobe bronchus (Figure 4). Mucosal irregularity of right middle bronchus (vascular). Trans bronchial needle aspirate of lymph nodes shows negative for malignancy and tuberculosis. Once the patient was stabilized, she was referred to paediatric surgery for VATS and biopsy for further evaluation and management.

## DISCUSSION

Kartagener's syndrome is an autosomal recessive disorder characterised by dextrocardia, situs inversus, bronchiectasis, and sinusitis first described by Siewert in 1903 and therefore some people call it Siewert syndrome as well.<sup>1</sup> This was followed by another report by Oeri in 1909.<sup>2</sup> Kartagener reported four cases in 1933, and seven more in 1935. He was the first to point out that the occurrence of the triad was more than coincidental and that the incidence of bronchiectasis and sinusitis was proportionately more frequent in persons with situs inversus.<sup>3</sup>

KS is a congenital ciliary disorder inherited via autosomal recessive pattern and symptoms result from defective ciliary motility. Although the true incidence of the disease is unknown, it is estimated to be 1 in 32,000 Camner and et al.<sup>4,5</sup> Eliasson et al, used the descriptive phase "Immotile cilia syndrome" to categorize male patients with sterility and chronic respiratory infection.<sup>6</sup> In 1981, Rossman et al, coined the term Primary Ciliary Dyskinesia (PCD) because some patients with KS had cilia that were not immobile but exhibited uncoordinated and inefficient movement pattern.<sup>7</sup> Current nomenclature classifies all congenital ciliary disorders as PCD in order to differentiate them from the acquired types. KS is a part of a larger group of disorders referred to as PCD.

Normal ciliary beating is necessary for visceral rotation during embryonic development. In patients with PCD, organ rotation occurs as a random event; therefore, half of the patients have situs inversus and another half have normal situs. Abnormal ciliary motility results in general impairment of respiratory defence mechanism causing recurrent upper and lower respiratory tract infections. In abnormalities of cilia, structural abnormalities of dynein arms are the most common although abnormalities of the radial spoke and microtubules can also account for the condition.<sup>8</sup> In rare cases no structural ciliary abnormality is detectable even though the ciliary function is abnormal and the clinical syndrome is typical.<sup>9,10</sup> Patients with KS may have either situs solitus, i.e. dextrocardia only or situs inversus totalis where all the viscera are on the opposite side including left-sided appendix.<sup>11,12</sup>

The diagnostic criteria recommended for this syndrome are a history of chronic bronchial infection and rhinitis from early childhood combined with one more of the, following features: (a) situs inversus or dextrocardia in a patient or a sibling, (b) living but immobile spermatozoa, (c) tracheobronchial clearance which is absent or nearly

so, (d) cilia with ultra-structural defects characteristic of this syndrome.<sup>13</sup> This case had all features except immotile sperms as she was a female.

Electron microscopic analysis of the ultra-structure of the cilia can complete the diagnostic workup of the patient. However, it needs invasive procedures like biopsies from nasal mucosa or trachea. Also, chronic infection may damage cilia, resulting in non-diagnostic findings. Amongst other diagnostic methods, only the "Saccharine test" is the one which can be performed easily. The saccharine test is an inferential test of ciliary dysfunction.<sup>13</sup>

The clinical features of primary dyskinesia such as productive cough, pulmonary infections, sinusitis, otitis media, and infertility have been ascribed to the reduced clearance of mucus in the airways and sinuses and impaired motility of the sperm, respectively. Bronchiectasis and chronic infections may result in end-stage pulmonary disease with dyspnoea and heart failure.<sup>14</sup> Like other patients suffering from Kartagener's syndrome, our patient had a long history of recurrent bronchial and pulmonary infections from early childhood on.

Clinical evidence of bronchiectasis with productive cough occurs in fewer than 10% of children aged less than 9 years, versus 75% in affected adult patients.<sup>15</sup> The most frequent symptom of bronchiectasis is a chronic and productive cough. Streaks of blood in the sputum are common. Serious haemoptysis may occur due to exacerbation of chronic bacterial infection with necrosis of the mucosa. The sputum cultures obtained from bronchoscopy were without evidence of bacteria in our patient. Neither clinical nor electrocardiographic signs of pulmonary, another possible cause of haemoptysis in patients with Kartagener's syndrome, were detected.<sup>16</sup>

Here we report a case of recurrent onset of haemoptysis in a young patient with Kartagener's syndrome. Because repeated bronchoscopy did not reveal the location of bleeding and other parts of the lung were also afflicted by bronchiectasis, and with the exception of an area of small irregular arteries of the left mid zone originating from the left bronchial artery, no areas suspicious for bleeding were found. Therefore embolization of the middle lobe arteries was not performed. Obviously, the location of bleeding was not reached by the bronchoscope due to compression of the bronchus. The chronic inflammation of the bronchus wall probably led to erosion of a bronchial artery branch.

Treatment of this rare congenital disorder includes antibiotics (intravenous or oral), intermittent or continuous used to treat upper and lower airway infections.<sup>17</sup> Inhaled bronchodilators, mucolytic, and chest physiotherapy are used to treat bronchiectasis/lower respiratory tract infections.<sup>18,19</sup> A role for inhaled or oral corticosteroids and recombinant DNA is anecdotal.<sup>20</sup> Pneumococcal and H influenza vaccination is preferred

and advised to decrease both the severity and frequency of infections.<sup>21</sup> Surgical care includes tympanostomy tubes to reduce recurrent infections/conductive hearing loss.<sup>22</sup> Pulmonary surgery in form of lobectomy, lingulectomy and or segmentectomy has been tried with some success in selected cases.<sup>23</sup> Lung transplantation and heart-lung transplantation may provide hope of prolonging life in severe cases.<sup>24</sup>

## CONCLUSION

It is important to consider the diagnosis of Kartagener syndrome in a child or young adult who presents with a history of recurrent respiratory tract infections coupled with chronic sinusitis and febrile illness associated with impaired mucociliary clearance and sterility or impaired fertility.

Physicians should be aware of the possible serious complication of severe haemoptysis in young patients with Kartagener's syndrome. Angiography should be considered as a potential diagnostic tool in such cases.

*Funding: No funding sources*

*Conflict of interest: None declared*

*Ethical approval: Not required*

## REFERENCES

- Siewert AR. Über einem fall von bronchiectasie bei sinem patienten mit situs inversus viscerum. Berl Klin Wochenschr. 1903;41:139.
- Oeri R. Zur kasvinistik des situs viscerum inversus totalis. Ztschr F Path Wissensch. 1909;3:393.
- Kartagener M. Zur pathogenese der bronchiectasien: 1. Mittleilung: bronchiectasien bei situs viscerum inversus. Beitr Klin Tuberk. 1933;38:849.
- Kartagener M, Horlacher A. Bronchiectasien bei situs viscerum inversus. Schweiz Med Wschr. 1935;65:782.
- McManus IC, Mitchison HM, Chung EM. Primary ciliary dyskinesia (Siewart's/Kartagener's syndrome): respiratory symptoms and psycho-social impact. BMC Pulm Med. 2003;3:4.
- Guerrant JL, Douty T, Tegetmeyer C, Jahrsdoefer RA. Bronchiectasis in the immotile cilia syndrome. New Eng J Med. 1978;298:282.
- Afzelius BA. A human syndrome caused by immotile cilia. Sci. 1976;193:317-9.
- Herzon F, Murphy S. Normal ciliary ultrastructure in children with Kartagener's syndrome. Ann Otol Rhino Laryng. 1980;89:81-3.
- Schidlow DV, Katz SM. Immotile cilia syndrome. New Eng J Med. 1983;308:595.
- Barthwal MS. Kartagener's syndrome in a fertile male - an uncommon variant. Lung India. 2006;23:123-5.
- Tsang KW, Zheng L, Tipoe G. Ciliary assessment in bronchiectasis. Respirol. 2000;5:91-8.
- Noone PG, Bali D, Carson JL, Sannuti A, Gipson CL, Ostrowski LE, et al. Discordant organ laterality in monozygotic twins with primary ciliary dyskinesia. Am J Med Genet. 1999 Jan 15;82(2):155-60.
- Mahsud I, Shahab-ud-Din. Kartagener's syndrome: a case report. Gomal J Med Sci. 2006;4(2):79-81.
- Miller RD, Divertie MB. Kartagener's syndrome. Chest. 1972;62:130-5.
- Ooi GC, Khong PL, Chan-Yeung M, Ho JC, Chan PK, Lee JC, et al. High-resolution CT quantification of bronchiectasis: clinical and functional correlation. Radiol. 2002 Dec;225(3):663-72.
- Logan WD, Abbott OA, Hatcher CR. Kartagener's triad. Chest. 1965;48:613-6.
- Rosen MJ. Chronic cough due to bronchiectasis: ACCP evidence based clinical practice guidelines. Chest. 2006;129:122S-31S.
- Sharma B, Sharma M, Bondi E, Sharma M. Kartagener's syndrome associated with Allergic Bronchopulmonary Aspergillosis. Medscape Gen Med. 2005;7(2):25.
- Imafuku T, Ogihara T, Kudo H, Hayashi K, Ohtake KI, Iyori S. Kartagener's syndrome associated with infundibular pulmonic stenosis, chronic renal failure and azoospermia: a report of a case. Japanese J Med. 1986;25(2):195-8.
- Vahdani P, Abbasi F, Mousavipour F, Gholamin S, Korouni FS. Multiple lung abscesses in a patient with Kartagener's syndrome. Tanaffos 2008;7(4):64-7.
- Ugwu RO, Eneh AU, Otaigbe BE. Kartagener's syndrome: An unusual cause of respiratory distress in the newborn. Niger J Med. 2006;15(4):444-7.
- Gupta S, Handa KK, Kasliwal RR, Bajpai P. A case of Kartagener's syndrome: Importance of early diagnosis and treatment. Indian J Human Genet. 2012;18(2):263-7.
- Taiana JA, Villegas AH, Schieppati E. Kartagener's syndrome: Report of a case treated by pulmonary resection; review of literature. J Thoracic Surg. 1955;30:34-43.
- Ötgün I, Karnak I, Tanyel FC, Şenocak ME, Büyükpamukçu N. Surgical treatment of bronchiectasis in children. J Pediatr Surg. 2004 Oct 1;39(10):1532-6.

**Cite this article as:** Mohinish S , Mallesh K , Prashanth HK , Ravichandra KR. Severe haemoptysis in a 5 year old child with Kartagener's syndrome: case report. Int J Contemp Pediatr 2020;7:462-5.