

Case Report

Neonatal ovarian cyst complicating as subacute intestinal obstruction: a case report

Goutam Chakraborty*, Anwesa Chakraborty, Nidhi Sugandhi, Amit Jadhav,
S. K. Acharya, Deepak Bagga

Department of Pediatric Surgery, Vardhman Mahavir Medical College and Safdarjung Hospital, New Delhi, India

Received: 30 November 2019

Accepted: 09 December 2019

*Correspondence:

Dr. Goutam Chakraborty,

E-mail: drgoutam83@yahoo.com

Copyright: © the author(s), publisher and licensee Medip Academy. This is an open-access article distributed under the terms of the Creative Commons Attribution Non-Commercial License, which permits unrestricted non-commercial use, distribution, and reproduction in any medium, provided the original work is properly cited.

ABSTRACT

Congenital Ovarian cysts are among the commonest intra-abdominal masses encountered in fetuses on antenatal screening, mostly during the third trimester of pregnancy. Though the etiology remains unknown, the most prevalent hypothesis holds maternal hormonal stimulation responsible for the pathology. Most are asymptomatic but potential complications can be life-threatening. A case of a 7 day old female baby was reported with normal antenatal scans and complaints of abdominal distension and vomiting since day 1 of life. Imaging included a Ultrasonographic diagnosis of suspected ovarian lesion and an MRI diagnosis of omental cyst. Due to progressive abdominal distension, authors proceeded with laparotomy. Left salpingo-oophorectomy was done as no ovarian tissue was salvageable. Post-operative period was uneventful. The histopathological picture was that of benign follicular cyst of ovary.

Keywords: Abdominopelvic lump, Follicular cyst, Neonatal ovarian cyst, Salpingo-oophorectomy

INTRODUCTION

Ovarian cysts are one of the commonest intra-abdominal masses diagnosed on ultrasonography in female fetuses in utero and female neonates.^{1,2} Most are incidental findings.³ Occasionally complications such as torsion, haemorrhage, necrosis, rupture, bowel obstruction, respiratory distress or compression of IVC by a large cyst may occur, torsion being the commonest.^{4,5}

Management varies depending on presentation and size of cyst. Symptomatic ovarian Cysts larger than 5cm or with complex morphology are managed surgically while simple asymptomatic cysts lesser than 5cm may be followed up with regular ultrasonography till resolution which usually occurs by the first year of life. Surgery may be required if complications set in during follow-up.

The patient presented with progressive abdominal distension and intolerance to feeds since birth. The case had to be managed by exploratory laparotomy due to the significant size of the cyst (approximately 10x8 cm in size) which was excised in toto by left salpingo-oophorectomy. Post-operative recovery was uneventful, and baby could be discharged healthy by 3 days.

CASE REPORT

A 7-day old baby girl was referred to us from the nursery at the hospital with complaints of vomiting and progressive abdominal distension starting at 24hours of life. There was history of bilious NG output. Baby was born at 40 weeks to a 20-year-old primigravida with no associated comorbidities and weighed 3 kgs. The foetal antenatal scans had all been within normal limits. There

was no history of maternal exposure to any hormonal drugs during pregnancy. At examination, the child was reasonably active but not tolerating oral feeds. Nasogastric tube aspirate was bile tinged. Abdomen was distended but there was no visible bowel loop. On palpation, there was a mass, approximately 8x8 cms predominantly over hypogastrium, right iliac fossa and right lumbar region, soft with some mobility.

Investigations revealed all normal blood parameters. Sepsis screen was negative. X-ray chest and abdomen was indicative of displacement of bowel loops towards left hypochondrium and flank with opacity involving right flank and pelvis (Figure 1).

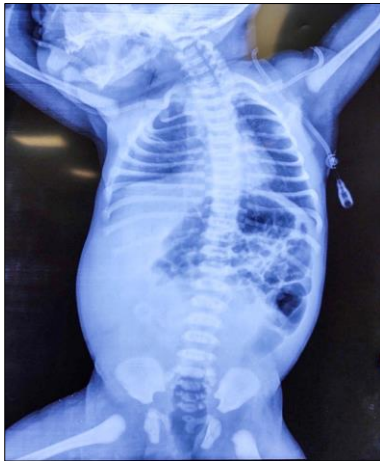

Figure 1: X-ray abdomen showing lower abdomen mass with displaced bowel loops.

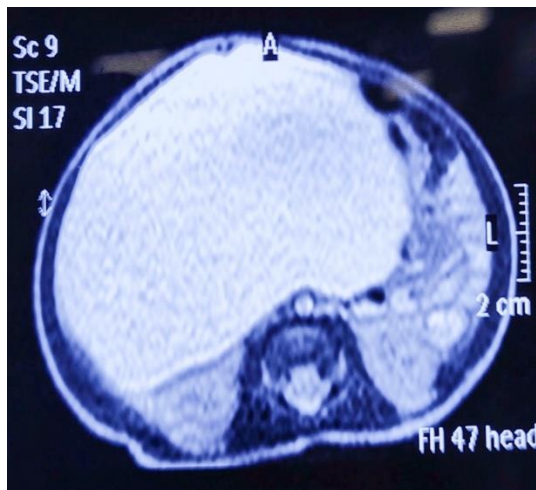


Figure 2: Bowel loops pushed superolaterally (Coronal view).

Ultrasonography showed a large cystic abdominopelvic lesion arising from pelvis and reaching up to subhepatic region with few follicle-like structures seen towards the periphery of the lesion, possibly daughter cysts. Bowel loops were displaced to the left side. Other organs were grossly imaged as normal. MRI abdomen was done for

further workup on radiological advice. It showed evidence of a large intraperitoneal lesion 7.4x9.2x6.1 cms (CCxTransxAP) displacing bowel loops superolaterally towards left. Lesion was hypointense on T1 and hyperintense on T2; suppressed on SPIR, without any blooming, non-enhancing on post contrast T1W. No evidence of calcification, septation or solid components were noted. Fat planes around lesion were maintained with moderately dilated bowel loops (Figure 2,3). Diagnostic possibilities included omental cyst and ovarian cyst (side could not be confirmed but impression was that of a right sided mass).

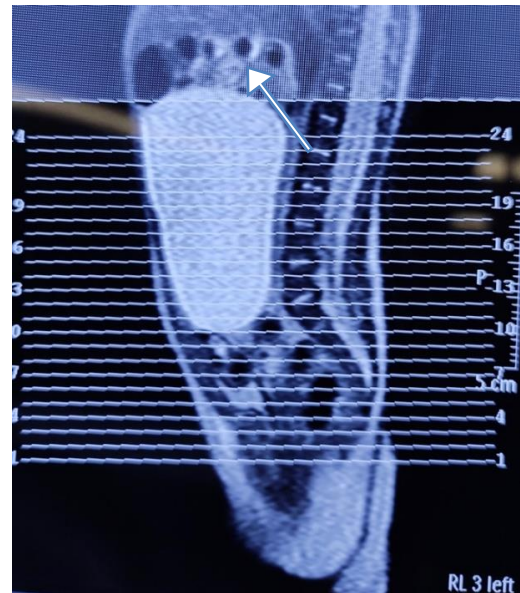

Figure 3: Bowel loops (white arrow) pushed superolaterally (Sagittal view).

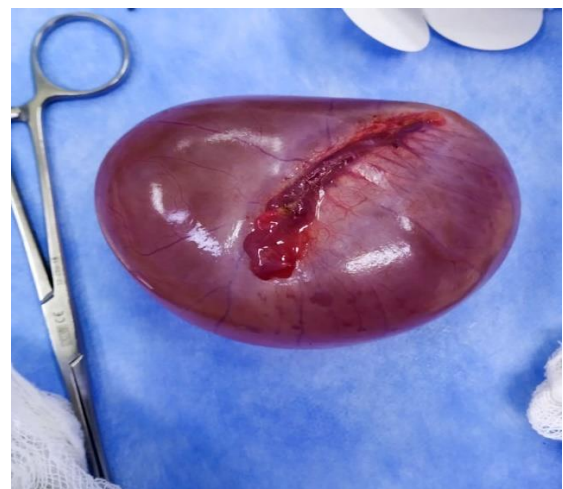

Figure 4: Specimen after Salpingo-oophorectomy.

With these provisional diagnoses, patient was taken up for surgery in view of progressive abdominal distension while maintaining adequate hydration and transit protocol. Exploratory laparotomy was done through right upper transverse incision under General Anesthesia with

Caudal block. Primary impression though was that of a right sided SOL, intraoperatively, a large left ovarian cyst was found. Dimensions were 10x8x8cm. Although it was arising from the left ovary, it was predominantly occupying the right lower quadrants.. The right sided ovary and Fallopian tube were normal. Left salpingo-oophorectomy was done as no ovarian tissue was salvageable and abdomen was closed in layers (Figure 4).

Histopathological examination of the specimen revealed features suggestive of benign follicular cyst of left ovary with no signs of atypia (Figure 5).

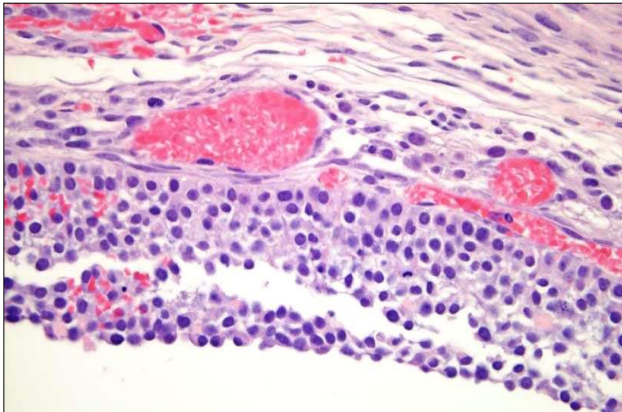


Figure 5: HPE slide showing benign follicular cyst.

The neonate had an uneventful recovery and she was discharged in good health on POD-3.

DISCUSSION

Ovarian cysts are one of the most frequently diagnosed perinatal intraabdominal lesions. The incidence of antenatally diagnosed ovarian cysts is 1 in 2500 live births.¹⁻³ There appeared to be an association with maternal diabetes and Rhesus isoimmunization in one study.⁴ But no such association has been confirmed in several large series of ovarian cysts that were diagnosed at pre- natal period in the US.⁵

There is no consensus regarding the etiopathogenesis of ovarian cysts. They generally manifest in the third trimester and are thought to be a consequence of exposure to fetal pituitary gonadotropins, placental human chorionic gonadotropins, and maternal estrogens which stimulates the fetal ovary and causes follicle production and maturation.⁶ Enríquez et al, have suggested primitive gonadal dysgenesis due to vascular compromise to be the underlying etiopathology for complex ovarian cysts.⁷ Postnatal surgical and histologic analysis of six cases of complex ovarian cysts demonstrated a high position in the abdomen, with features corresponding to the 5-6-week embryonic stage in four specimens and to the 20-week embryonic stage in two specimens. There is a risk of pulmonary hypoplasia developing in fetuses with large cysts as with other

lesions which compress and reduce the intrathoracic space.⁸ The infantile pelvis is shallow and thus the ovary is an abdominal organ and more prone to torsion than the postpubertal ovary.

The approach used by radiologists to construct a differential diagnosis is to be oriented according to the organ in which the mass originates. However, in the fetus, due to the small size, normal changes in developmental anatomy, and the paucity of intra-abdominal fat, it is difficult to differentiate intraabdominal organs from one another. Therefore, the cystic versus solid approach works very well in evaluation of fetal abdominal masses.⁹ The differential diagnosis for a cystic abdominal mass in any fetus includes renal cyst, ureterocele, urinoma, urachal anomalies, dilated bowel, meconium cyst, enteric duplication cyst, lymphangioma, choledochal cyst, and cystic neuroblastoma.¹⁰ Ovarian cyst and hydrocolpos are seen only in female fetuses. An abnormally distended bladder is more likely to be seen in a male fetus with posterior urethral valves or prune belly syndrome.

An ovarian cystic structure less than 20 mm in diameter is considered to be a maturing follicle and is thus considered physiologic rather than pathologic. Only a cyst larger than 20 mm in diameter is considered abnormal.⁵ The “daughter cyst” sign describes a small, round, anechoic structure within a cyst and is reported to be pathognomonic for ovarian cysts.^{11,12}

The treatment of ovarian cysts in the newborn is highly debatable with no consensus on the management. Roughly, it depends on the size at diagnosis, symptomatology and morphological characteristics. The current clinical approach is to adopt a conservative stance with regular monitoring of dimensions of cyst with an eye on development of clinical signs and symptoms of complications. For complex cysts or cysts larger than 5cm, a more proactive approach is helpful with laparoscopy being the current operative standard of care. Laparoscopy has the advantage of minimal invasive nature and prompt recovery in children. For selected cases where rupture maybe anticipated in attempt to establish pneumoperitoneum or in emergency setting , a laparotomy is indicated.

Cysts less than 5 cm in diameter are unlikely to get complicated and can be observed for spontaneous resolution with serial ultrasound every 4-6 weeks. Large cysts (>5 cm) have a high risk of complications (compression, torsion, hemorrhage) and often present with pain, vomiting and abdominal distention. So it is recommended that these cysts should be punctured or removed surgically.^{13,14} Zampieri et al, showed a strong correlation between cysts with size more than 5cm and need for surgical management.¹⁵ If a foetal ovarian cyst is diagnosed, serial ultrasound for monitoring of cyst dimensions and echogenicity is advocated. Foetal cyst aspiration, though controversial, has been recommended

by Bagolan et al, if the cyst diameter is more than 5cm or size increases by more than 1cm/week.¹⁶ This is to prevent risks of torsion or rupture in large ovarian cysts.

CONCLUSION

Neonatal intra-abdominal SOLs are a reasonably common finding in perinatal scans. Whereas most are incidental findings, yet, they have the potential to cause significant morbidity due to associated complications. Symptomatology, if any, depends on the organ from which it arises. Neonatal ovarian cyst are not rare findings in female neonates. Its etiology has not been confirmed yet. Most resolve spontaneously. Clinical manifestations occur when the cyst is large or enlarging and when it has a complex morphology. Any complication arising thereby puts the involved tubo-ovary at risk of sacrifice and hence significant morbidity. Apart from surgical follow-up, these patients may benefit from gynaecological follow-up as well, specially during peripubertal period. This is to ensure a healthy solitary ovary and avoid fertility related complications later.

Funding: No funding sources

Conflict of interest: None declared

Ethical approval: Not Required

REFERENCES

1. Singal AK, Vignesh KG, Paul S, Matthai J. Antenatally diagnosed ovarian cyst with torsion managed laparoscopically. J Indian Assoc Pediatr Surg. 2008;13:28-9.
2. Brandt ML, Helmrath MA. Ovarian cysts in infants and children. Semin Pediatr Surg. 2005;14:78-85.
3. Katara AN, Shah RS, Bhandarkar DS, Shaikh S. Laparoscopic management of antenatally-diagnosed abdominal cysts in newborns. Surg Laparo Endo Percutaneous Tech. 2004 Feb 1;14(1):42-4.
4. DeSa DJ. Follicular ovarian cysts in stillbirths and neonates. Arch Dis Childhood. 1975 Jan 1;50(1):45-50.
5. Bagolan P, Giorlandino C, Nahom A, Biolancioni E, Trucchi A, Gatti C, et al. The management of fetal ovarian cysts. J Pediatr Surg. 2002;37(1):25-30.
6. Bryant AE, Laufer MR. Fetal ovarian cysts: incidence, diagnosis and management. J Reproductive Med. 2004 May;49(5):329-37.
7. Enríquez G, Durán C, Torán N, Piqueras J, Gratacós E, Aso C, et al. Conservative versus surgical treatment for complex neonatal ovarian cysts: outcomes study. Am J Roentgenol. 2005 Aug;185(2):501-8.
8. Landrum BO, Ogburn JP, Feinberg SA, Bendel RI, Ferrara BR, Johnson DE, Thompson TR. Intrauterine aspiration of a large fetal ovarian cyst. Obstet Gynecol. 1986 Sep;68(3 Suppl):11S-4S.
9. Woodward PJ. Cystic abdominal mass. In: Woodward PJ, ed. Expert DDx obstetrics. Salt Lake City; Utah: Amirsys; 2009:32-37.
10. Woodward PJ. Solid abdominal mass. In: Woodward PJ, ed. Expert DDx obstetrics. Salt Lake City; Utah: Amirsys; 2009:38-39.
11. Quarello E, Gorincour G, Merrot T, Boubli L, d'Ercole C. The 'daughter cyst sign': a sonographic clue to the diagnosis of fetal ovarian cyst. Ultrasound Obstet Gynecol: Official J Inter Soc Ultrasound Obstet Gynecol. 2003 Oct;22(4):433-4.
12. Lee HJ, Woo SK, Kim JS, Suh SJ. Daughter cyst sign: a sonographic finding of ovarian cyst in neonates, infants, and young children. Am J Roentgenol. 2000 Apr;174(4):1013-5.
13. Schamahmann S, Haller JO. Neonatal ovarian cysts: pathogenesis, diagnosis and management. Pediatr Radiol. 1997;27:101-5.
14. Mukhopadhyay M, Shukla RM, Mukhopadhyay B, Mandal KC, Ray A, Sisodiya N, et al. Ovarian cysts and tumors in infancy and childhood. J Indian Assoc Pediatr Surg. 2013;18:16-9.
15. Zampieri N, Borruto F, Zamboni C, Camoglio FS. Foetal and neonatal ovarian cysts: a 5-year experience. Arch Gynecol Obstetr. 2008 Apr 1;277(4):303-6.
16. Bagolan P, Giorlandino C, Nahom A, Bilancioni E, Trucchi A, Gatti C, Aleandri V, Spina V. The management of fetal ovarian cysts. J Pediatr Surg. 2002 Jan 1;37(1):25-30.

Cite this article as: Chakraborty G, Chakraborty A, Sugandhi N, Jadhav A, Acharya SK, Bagga D. Neonatal ovarian cyst complicating as subacute intestinal obstruction: a case report. Int J Contemp Pediatr 2020;7:454-7.