

## Case Report

# Neonatal *Leuconostoc lactis* meningitis

Senthil Kumar Arumugam<sup>1\*</sup>, Kaviyarasan Govindharaj<sup>2</sup>

Department of <sup>1</sup>Neonatology, <sup>2</sup>Microbiology, Ramalingam Hospital, Salem, Tamil Nadu, India

**Received:** 07 June 2021

**Revised:** 10 August 2021

**Accepted:** 12 August 2021

### \*Correspondence:

Dr. Senthil Kumar Arumugam,

E-mail: drsensalem99.sk@gmail.com

**Copyright:** © the author(s), publisher and licensee Medip Academy. This is an open-access article distributed under the terms of the Creative Commons Attribution Non-Commercial License, which permits unrestricted non-commercial use, distribution, and reproduction in any medium, provided the original work is properly cited.

## ABSTRACT

*Leuconostoc lactis* has a low potential for human infection, although serious infections have been documented in immunocompromised persons. The source of this organism is a dairy product. A 3-day old neonate was presented with multifocal clonic seizures who were given formula feed from birth. We isolated *Leuconostoc lactis* in his Cerebrospinal fluid (CSF), which is resistant to vancomycin. *L. lactis* meningitis was treated successfully with the injection of ampicillin-sulbactam.

**Keywords:** *Leuconostoc lactis*, Meningitis, Neonate

## INTRODUCTION

We report a case of *Leuconostoc lactis* meningitis in a 3-day old male neonate. Few cases of *Leuconostoc* species sepsis are reported among preterm neonates.<sup>1</sup> *Leuconostoc lactis* is a gram-positive-cocci that is intrinsically resistant to vancomycin. It is rarely pathogenic and can cause serious infections in immune-compromised hosts. Early identification of this organism and treatment with appropriate antibiotic is necessary for better outcome.<sup>2</sup>

## CASE REPORT

A 3-day old male neonate was admitted for neonatal seizures. He was born by emergency cesarean section as the mother had uterine scar tenderness. He weighed 3.3 kg at birth and was given formula feed from day 1 of life. He had 3 episodes of multifocal clonic seizures on day 2 of life. He was given intravenous (iv) phenobarbitone and loading dose of IV levitracetam, followed by maintenance dose. There were no further episodes of convulsion after admission.

Investigation showed hemoglobin of 13.9 g/dl, white blood cell count of 8600/cu mm, platelet count of 3 lakh/cu mm. Serum calcium was 10 mg/dl, C-reactive protein was 62 mg/L. Electrolytes were serum sodium of 137 mmol/L, potassium of 3 mmol/L, chloride of 110 mmol/L, and bicarbonate of 22 mmol/l. Serum lactate was 23 mg/dl.

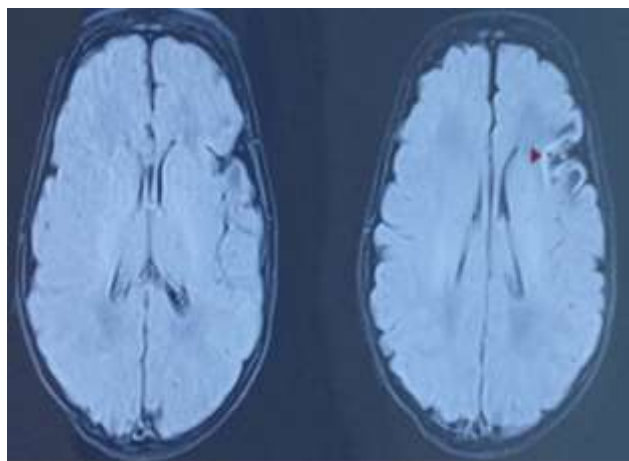
Cerebrospinal fluid analysis showed turbid appearance with WBC count of 48 cells/cu mm, neutrophils of 55%, lymphocyte of 45%, glucose of 53 mg/dl, protein of 49 mg/dl. Blood culture was sterile. Magnetic resonance Imaging of brain after 14 days of iv antibiotic showed gyriform pial parenchymal enhancement with vasogenic edema in underlying subcortical white matter in left frontoparietal cortex suggestive of resolving meningitis (Figure 1). He received injection ampicillin-sulbactam for 21 days. Neurological examination was normal at time of discharge.

### Isolation and identification

Under aseptic precautions, CSF fluid was inoculated into the sheep blood agar plate and Macconkey agar plate.

Catalase-negative, oxidase-negative, small, circular, grey colored alpha-hemolytic colonies appeared on sheep blood agar after the incubation period of 48 hours. Gram staining showed gram positive cocci. *Leuconostoc lactis* was identified using PMIC-84 panel of BD phoenix M50 which utilizes a series of conventional chromogenic and fluorogenic biochemical tests

*L. lactis* was sensitive to amikacin, gentamicin, ampicillin-sulbactam, amoxicillin-clavulanate, methicillin, cefotaxime, linezolid and resistant to azithromycin, ciprofloxacin, vancomycin.



**Figure 1: Gyriform pial parenchymal enhancement with vasogenic edema in underlying subcortical white matter in left frontoparietal cortex.**

## DISCUSSION

*Leuconostoc* species are catalase negative facultative anaerobic gram positive cocci, placed within the family *Leuconostocaceae*. The *Leuconostoc* species that are known to cause human infections are *L. lactis*, *L. citreum*, *L. mesenteroides*, *L. pseudomesenteroides*, and *L. paramesenteroides*.<sup>3</sup> It is widely present in soil and vegetables and used in the production of wine and dairy products. *Leuconostoc* spp. are frequently misidentified as *Streptococcus viridians*.<sup>4</sup>

The primary source of *Leuconostoc lactis* is dairy products. It is rarely pathogenic, although serious infections are reported among immunocompromised persons. Omari et al reported a case of *Leuconostoc lactis* meningitis in a 62-year-old immunocompromised man with successful outcome.<sup>2</sup> Sarmento-Ortiz et al reported infective endocarditis in an infant with short bowel syndrome caused by *Leuconostoc lactis*.<sup>5</sup> Friedland et al reported a fatal case of meningitis in one month old female infant caused by *Leuconostoc mesenteroides*.<sup>6</sup>

The portal of entry of this organism is mainly through the gastrointestinal tract. The predisposing conditions for this infection are short bowel syndrome, presence of central

catheters, long-term parenteral nutrition, and immune-deficiency conditions.

It is intrinsically resistant to vancomycin as it produces a peptidoglycan ending in D-Ala-D-Lac.<sup>7</sup>

In our case, he presented with multifocal clonic seizures and *Leuconostoc lactis* was isolated in CSF. He was treated with injection ampicillin-sulbactam for 21 days. Neurological examination was normal at discharge.

The risk factor associated in our case was formula feeding given from birth. We could not send a formula feed sample for culture, as it was unavailable at the time of diagnosis. The possible source could have been contamination while preparing the feed. Rubin et al. isolated *Leuconostoc lactis* from the cartons of the infant formula.<sup>8</sup>

## CONCLUSION

*Leuconostoc lactis* can cause serious infection in immunocompromised individuals especially in neonates. The source of this organism is dairy products. Early identification of the organism and treatment with ampicillin is the cornerstone of the management.

## ACKNOWLEDGEMENTS

Author would like to thank Dr. Suresh, Deepam hospital, Salem, Dr. Raeshmi, consultant pediatrician, Ramalingam hospital, Salem for assistance with diagnosis, and patient management.

*Funding: No funding sources*

*Conflict of interest: None declared*

*Ethical approval: Not required*

## REFERENCES

1. Janow G, Lambert B, Scheiner M, Rosen O, Goldman DL, Soghier L. *Leuconostoc* septicemia in a preterm neonate on vancomycin therapy: case report and literature review. Am J Perinatol. 2009;26(1):89-91.
2. Omori R, Fujiwara S, Ishiyama H, Kuroda H, Kohara N. *Leuconostoc lactis*-A Rare Cause of Bacterial Meningitis in an Immunocompromised Host. Intern Med. 2020;59(22):2935-6.
3. Principles and practice of infectious diseases, 7<sup>th</sup> ed. Mandell GL, Bennett JE, Dolin R, Eds. Churchill Livingstone Elsevier, Philadelphia. 2010;2652-3.
4. Handwerker S, Horowitz H, Coburn K, Kolokathis A, Wormser GP. Infection due to *Leuconostoc* species: six cases and review. Rev Infect Dis. 1990;12(4):602-10.
5. Sarmento-Ortiz EA, Oliveros-Andrade OA, Rojas-Hernandez JP. Endocarditis por *Leuconostoc lactis* en un lactante: reporte de caso. Rev Fac Med. 2020;68(3):467-70.

6. Friedland IR, Snipelisky M, Khoosal M. Meningitis in a neonate caused by *Leuconostoc* spp. J Clin Microbiol. 1990;28(9):2125-6.
7. Park IS, Walsh CT. D-Alanyl-D-lactate and D-alanyl-D-alanine synthesis by D-alanyl-D-alanine ligase from vancomycin-resistant *Leuconostoc mesenteroides*. Effects of a phenylalanine 261 to tyrosine mutation. J Biol Chem. 1997;272(14):9210-4.
8. Rubin LG, Vellozzi E, Shapiro J, Isenberg HD. Infection with vancomycin-resistant "*Streptococci*" due to *Leuconostoc* species. J Infect Dis. 1988;157(1):216.

**Cite this article as:** Arumugam SK, Govindharaj K. Neonatal *Leuconostoc lactis* meningitis. Int J Contemp Pediatr 2021;8:1619-21.