

## Review Article

# Rhinogenic contact point headache in pediatric age group: a review

Santosh Kumar Swain\*, Prasenjit Baliarsingh

Department of Otorhinolaryngology and Head and Neck Surgery, IMS and SUM Hospital, Siksha “O” Anusandhan University, Bhubaneswar, Odisha, India

**Received:** 21 November 2021

**Accepted:** 14 December 2021

### \*Correspondence:

Dr. Santosh Kumar Swain,

E-mail: [santoshvoltaire@yahoo.co.in](mailto:santoshvoltaire@yahoo.co.in)

**Copyright:** © the author(s), publisher and licensee Medip Academy. This is an open-access article distributed under the terms of the Creative Commons Attribution Non-Commercial License, which permits unrestricted non-commercial use, distribution, and reproduction in any medium, provided the original work is properly cited.

## ABSTRACT

Headache is a common clinical entity of pediatric patients in routine clinical practice. Anatomical variation in the nasal cavity may result in headaches due to contact of the opposing mucosal surfaces, called rhinogenic contact point headache (RCPH). RCPH has recently begun to be of interest among clinicians and is accepted as a cause of headache by international headache society classification. The pressure of the two opposing mucosal surfaces in the nasal cavity without any evidence of inflammation can be an etiology for headache or facial pain. Anatomical variations in the nasal cavity like deviated nasal septum (DNS), spur, concha bullosa, hypertrophied inferior turbinate, medialized middle turbinate, and septal bullosa are important causes for contact point headache. RCPH is often misdiagnosed by clinicians during the assessment of headaches in pediatric patients and is sometimes considered a headache of unknown etiology. Endoscopic examination of the nasal cavity and computed tomography (CT) scans are important tools for the diagnosis of anatomical variations in the nasal cavity causing RCPH. Endoscopic resection of the contact point in the nasal cavity is the treatment of choice. There is not much literature for RCPH in pediatric patients, indicating that these clinical entities are neglected. This review article discusses the details of the epidemiology, etiopathology, clinical manifestations, diagnosis, treatment of the RCPH in pediatric patients.

**Keywords:** RCPH, Pediatric age, Deviated nasal septum, Septal spur, Middle turbinate concha bullosa

## INTRODUCTION

Headache is a commonly encountered symptom found in everyone's life.<sup>1</sup> Chronic headache is not an uncommon clinical entity in the pediatric age group and its etiological factors are also quite varied.<sup>2</sup> There are myriads of causes for manifesting headache in children such as migraine, refractory errors, tension headache, temporomandibular arthralgia, myofascial spasm, and brain tumors.<sup>3</sup> Headache can be classified as a primary and secondary headache. The primary headache has no specific etiology such as migraine, tension headache, and cluster headache.<sup>4</sup> The secondary headache is often due to infections, tumors, trauma, vascular lesions, and metabolic diseases.<sup>5</sup> RCPH is a painful sensation in the head and face because of an intranasal contact point without any inflammatory findings or mass lesions.<sup>6</sup> The pathogenesis of RCPH is still the subject of controversy.

It often required a multidisciplinary approach for getting the exact cause of headaches. RCPH is a secondary type of headache.<sup>6</sup> Any contact point between the lateral nasal wall and nasal septum may cause a headache which is called RCPH. The exact mechanism for headache was described as the release of substance P and stimulation of unmyelinated C fibers.<sup>7</sup> However, many workers rejected this mechanism.<sup>8</sup> So, the exact mechanism of the RCPH is still unclear. It is one of the debated clinical entities for causing headaches due to mucosal contact points in the nasal cavity.<sup>9</sup> RCPH can be considered as a potential cause for unexplained headaches. RCPH is often undiagnosed, even this etiology is not suspected on initial evaluation of the patient for headache. In absence of inflammation or sinusitis, the referred headache due to pressure on the nasal mucosa by anatomical variations in the nose occurs in RCPH.<sup>10</sup> RCPH is a newer type of headache in the international classification of headache

disorders (ICHD) supported by limited evidence. There is a paucity of literature related to RCPH in pediatric patients. This review article discusses the details of the epidemiology, etiopathology, clinical manifestations, diagnosis, treatment of the RCPH in pediatric patients.

## LITERATURE SEARCH

Multiple systematic methods were used to find current research publications on rhinogenic contact point headache in the pediatric age group. We started by searching the Scopus, Pub Med, Medline, and Google Scholar databases online. This search strategy recognized the abstracts of published publications, while other papers were discovered manually from the citations. A search strategy using PRISMA (Preferred reporting items for systematic reviews and meta-analysis) guidelines was developed. Randomized controlled studies, observational studies, comparative studies, case series, and case reports were evaluated for eligibility. There were total numbers of articles 68 (31 case reports; 27 cases series; 10 original articles). This paper focuses only on RCPH in pediatric patients. The search articles with RCPH in adult and elderly age groups or headaches other than RCPH are excluded in this review article. Review articles with no primary research data were also excluded. This paper examines the epidemiology, etiopathogenesis, clinical manifestations, diagnosis, and treatment of RCPH in pediatric patients. This analysis provides a foundation for future prospective trials for RCPH in the pediatric age group. It will also catalyse additional study RCPH in the pediatric age group, allowing early detection and treatment.

## EPIDEMIOLOGY

Rhinogenic-related headache has been documented since 1888.<sup>11</sup> However, not much attention has been given to this clinical entity until the introduction of the nasal endoscope and the use of CT scan in the nose and paranasal sinuses.<sup>12,13</sup> Intranasal contact points are found in approximately 4% of the nasal cavities.<sup>14</sup> DNS is the commonest type of anatomical variation causing headache (35.18%).<sup>15</sup> Second commonest anatomical variation causing headache was septal spur followed by middle turbinate concha bullosa, hypertrophied inferior turbinate, large ethmoidal bulla, pneumatized hypertrophied superior turbinate, medialized middle turbinate, and nasal septal bullosa.<sup>15</sup> The commonest location for headache in RCPH is the frontal area followed by the nose/ glabellar area.<sup>15</sup> Occipital area is very uncommon to be affected by the headache in RCPH.

## ETIOPATHOLOGY

There are multiple etiological factors responsible for headache such as tension headache, migraine, intracranial mass, glaucoma, refractory errors, temporomandibular joint arthralgia, myofascial spasm.<sup>16</sup> There are different types anatomical variations in the nasal cavity which

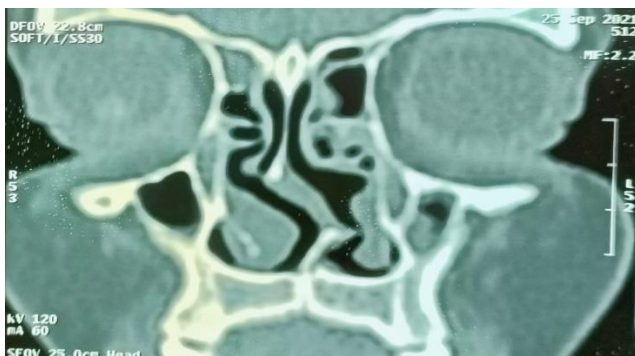
cause RCPH (Table 1). One study showed different types of nasal septal deviation and septal spurs among around 62% of cases of contact point headache.<sup>17</sup> Septal spur has a significant relationship with a headache. Hypertrophied inferior turbinate may also be the etiological factor. Other than septal spur and hypertrophied pneumatized middle turbinate, RCPH may also be caused by the contact between the mucosal lining of the nasal septum and superior turbinate or medial wall of the ethmoidal sinus.<sup>18</sup> Middle turbinate is an important landmark which forms the media wall of the ethmoidal sinus. The middle turbinate is associated with several functions such as humidification, moisturization of the nasal cavity, regulation of airflow and temperature, olfaction, and filtration.<sup>19</sup> There are different types of anatomical variations found in middle turbinate like pneumatized paradoxically curved, bifurcate, trifurcate, secondary, and accessory types, but hypertrophied pneumatized middle turbinate (concha bullosa) is the commonest type.<sup>20</sup> The etiopathogenesis of RCPH is still the subject of controversy. Mechanical irritants like pressure on the mucosal lining of the nasal cavity may result in the release of neuropeptides via central orthodromic impulse and peripheral local, antidromic impulse. The neuropeptides like substance P(SP) and calcitonin-related peptide (CGRP) cause vasodilatation and edema of the mucosal membrane of the nasal cavity, which again intensifies the pressure effects on the contact area. The release of neuropeptides from the central nervous system results in pain sensation, which is similar to migraine without aura. The onset and duration of the pain coincide with the beginning and duration of the nasal cycle.<sup>21</sup> SP, CGRP, and neurokinin are found in nociceptive fibers in the central nervous system and tri-germinal-vascular system. So, the contact point between the mucosal layers in the nasal cavity may cause secondary headaches. SP plays an important role in the pathophysiology of contact headaches. Release of SP causes vasodilatation, plasma extravasation, and perivascular inflammation and causes headache similar to migraine without aura.<sup>22</sup> Normally mucosal linings of the nasal cavity have a higher concentration of SP than chronic hyperplastic mucosa or polypoidal tissues. This explains why intranasal contact points that cause headaches are found seen in patients without rhinosinusitis.<sup>23</sup>

**Table 1: Anatomical variations in the nasal cavity of pediatric patients causing RCPH.**

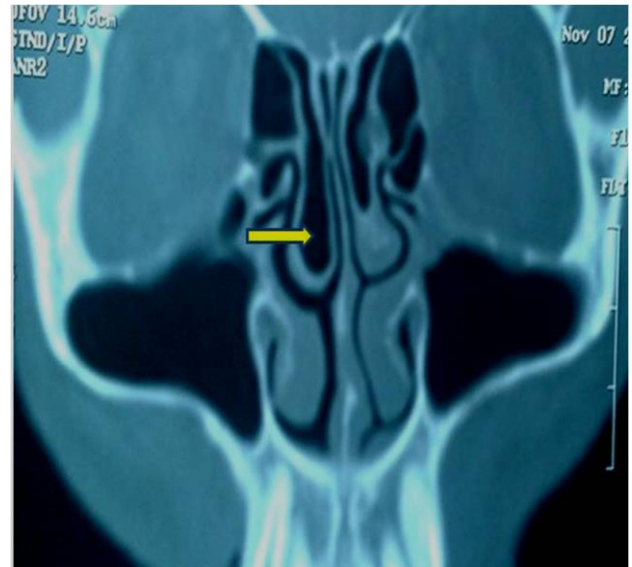
S. no.	Anatomical variations in the nasal cavity
1	Nasal septal deviation
2	Septal spur
3	Unilateral middle turbinate concha bullosa
4	Bilateral middle turbinate concha bullosa
5	Large ethmoidal bulla
6	Hypertrophied inferior turbinate
7	Hypertrophied superior turbinate
8	Nasal septal bullosa
9	Medialized middle turbinate

## CLINICAL PRESENTATIONS

RCPH is a painful sensation in the head and face due to intranasal contact points by opposing mucosal surfaces without any evidence of mass lesions or inflammatory findings. RCPH has often affected the quality of life. Deviated nasal septum (DNS) is a common anatomical variation in the nasal cavity.<sup>24</sup> DNS and nasal septal spur may result in referred headache and facial pain in the absence of inflammation.<sup>10</sup> DNS along with a variation of the middle turbinate is a common contributor for contact headache.<sup>10</sup> DNS also cause nasal obstruction in addition to headache. S-shaped DNS may cause bilateral contact points (Figure 1) which result in headache in both sides of facial region. Middle turbinate concha bullosa (Figure 2) is a common anatomical variant that may cause irritating contact point headache in children.<sup>2</sup> Concha bullosa occupies the space between the nasal septum and lateral wall of the nose, causing large areas of extensive mucosal contact. Intranasal mucosal contact between the middle turbinate concha bullosa or superior turbinate and nasal septum may cause stimulation of the sensory part of the trigeminal nerve and cause RCPH.<sup>25</sup> Middle turbinate concha bullosa impair the ventilation of the paranasal sinuses by blocking the osteomeatal complex and causing vacuum headaches and may result in sinusitis.<sup>26</sup> Middle turbinate concha bullosa may cause ocular or periorbital pain via the anterior ethmoidal nerve, which is a branch of the ophthalmic division of the trigeminal nerve.<sup>27</sup> The contact point headache by nasal septal spur has the highest severity in comparison to other types of contact points in the nasal cavity. Commonest site for referred headache in RCPH is frontal area followed by naso-facial region.<sup>15</sup> RCPH often present with intermittent pain localized in the periorbital and medial canthal or temporo-zygomatic areas. There is usually cessation of headache within 5 min following topical use of local anesthesia at contact area.<sup>28</sup> The headache in RCPH often mimics migraine with aura. This is why many individuals with RCPH are treated by neurologists and could not be cured.<sup>29</sup> Gross DNS or large middle turbinate concha bullosa often present with nasal obstruction. RCPH may give referred ear because common nerve supply of nasal cavity and ear such as trigeminal nerve (D2).<sup>30</sup>



**Figure 1: CT scan of nose and paranasal sinuses of S-shaped DNS with mucosal contact point in both nostrils.**



**Figure 2: CT scan of nose and paranasal sinuses of right-side middle turbinate concha bullosa.**

## DIAGNOSIS

RCPH is a secondary headache that encompasses different diagnostic definitions. The diagnostic criteria for RCPH are chronic headaches, no evidence of sinonasal disease except mucosal contact points in the nasal cavity, and demonstrable headache relief with the application of a topical anesthetic to the contact point area.<sup>30,31</sup> Application of local anesthetic agents at the contact point decreases the headache severity. In one study of 30 participants, 43% showed complete recovery of rhinogenic contact point headache with local application of anesthetic agents at mucosal contact points, 47% showed slight improvement and 10% showed no improvement of RCPH.<sup>10</sup> This is why RCPH can be properly diagnosed with an endoscopic examination of the nasal cavity and CT scan. Diagnostic nasal endoscopy along with a CT scan of the nose and paranasal sinuses is ideal for diagnosis of the anatomical variations of the nasal cavity. Rhinogenic contact point headache may be misdiagnosed, even this clinical entity is not suspected on preliminary evaluation. Diagnostic endoscopy and CT scan of the nose and paranasal sinus is useful to rule out sinusitis. CT scan is helpful to find out some pathologies which cannot be detected by physical examination and help to decide the exact site of contact points and the necessity of the surgery.<sup>32</sup> There is a nasal shrinkage test where nasal decongestant and topical anesthetics are applied at the mucosal contact points of the nasal cavity, however, some authors believe that this is an unreliable test.<sup>33</sup> In the absence of sinusitis, the referred headache is due to pressure on the nasal mucosal linings because of the anatomical variations in the nasal cavity.<sup>34</sup> The anatomical variations in the nasal cavity include spurs, concha bullosa, hypertrophied inferior turbinate, uncinata bulla, paradoxically middle turbinate, large ethmoidal bulla, uncinata bulla, medially or laterally bent uncinata process, paradoxically middle turbinate, enlarged



ethmoid bulla, paradoxically are thought to be the cause of headache. The cause behind the high prevalence of misdiagnosis of RCPH is unclear. This could potentially be because children do not have fully developed sinonasal tracts, limiting suspicion of rhinogenic pathology as the cause of headaches.

## TREATMENT

RCPH is an important cause of secondary headache which can be managed with surgical or medical treatment. The treatment of RCPH in pediatric age groups includes multidisciplinary approaches for early diagnosis and treatment of the etiological factors. Although topical nasal steroids relieve the rhinogenic contact point headache, long-term improvement needs surgical interventions. The topical nasal steroid improves the nasal patency on a short-term basis.<sup>35</sup> Few authors described the treatment of RCPH using transaction of fifth cranial nerve or injection of Gasserian ganglion by alcohol or novocaine.<sup>28</sup> Endoscopic lateral lamellectomy is the gold standard treatment for middle turbinate concha bullosa.<sup>36</sup> However, there is a chance of recurrence of contact points and synechia formation post-operatively resulting in frontal sinus diseases as a complication of this technique.<sup>37</sup> Before the era of endoscopic sinus surgery, complete removal of middle turbinate was done to manage the middle turbinate concha bullosa. In case DNS with headache is usually relieved by performing the septoplasty. Ethmoid bulla is the largest and anterior, and constant ethmoidal air cell. The ethmoidal bulla can be pneumatized and hypertrophied and cause contact with the middle turbinate. This is treated with help of a nasal endoscope. The endoscopic conchoplasty or anterior ethmoidectomy helps remove the contact point between the two opposing mucosal surfaces. Agger nasi cells are most anterior placed ethmoid air cells and found anterior superior to the attachment of middle turbinate at lateral of the nasal cavity. Hyper pneumatized agger nasi cells may cause contact to the mucosal surface of the nasal septum and cause contact headache. This contact point is easily treated surgically by an endoscopic approach. There is the resolution of the headache in less than seven days following excision of the mucosal contact points in the nasal cavity.<sup>28</sup> In one study, 66 patients were investigated for rhinogenic headache due to DNS, middle turbinate concha bullosa, and orbito-ethmoidal (Haller's) cell. They found a reduction of frequency and intensity of headaches after surgical excision of the contact points.<sup>38</sup> Chow et al found a reduction of severity and frequency of headache in 82% of cases.<sup>39</sup> Another study found a reduction of severity and frequency of headache in 91% of cases.<sup>40</sup>

## CONCLUSION

The diagnosis of the RCPH is often missed during clinical evaluation of the headache in the pediatric age group. Deviated nasal septum or septal spur are common anatomical variations in the nasal cavity for causing

RCPH. Other anatomical variations in the nasal cavities are middle turbinate concha bullosa and enlarged bulla ethmoidalis. The clinicians and pediatricians should keep in mind about RCPH during the diagnosis and treatment of headaches in pediatric patients. RCPH can be treated with medical or surgical treatment. Although topical nasal steroid relieves RCPH, long-term improvement is doubtful. Surgical excision of the contact points in the nasal cavity is preferred as a treatment modality for giving long-term outcomes.

*Funding: No funding sources*

*Conflict of interest: None declared*

*Ethical approval: Not required*

## REFERENCES

- Swain SK, Mohanty S, Sahu MC. Migraine-related vertigo in an elderly male. *Apollo Med.* 2018;15(2):112-5.
- Philipp J, Zeiler M, Wöber C, Wagner G, Karwautz AF, Steiner TJ et al. Prevalence and burden of headache in children and adolescents in Austria—a nationwide study in a representative sample of pupils aged 10-18 years. *J headache pain.* 2019 ;20(1):1-2.
- Swain SK, Behera IC, Sahoo L. Vestibular migraine: Our experiences at a tertiary care teaching hospital of Eastern India. *Med J Dr. DY Patil Vidyapeeth.* 2020;13(6):636-41.
- Swain SK, Achary S, Das SR. Vertigo in pediatric age: Often challenge to clinicians. *Int J Cur Res Rev.* 2020;12(18):136-41.
- Swain SK, Debta P, Lenka S, Samal S, Dani A, Mahapatra S. Vestibular migraine-A Challenging Clinical Entity. *Indian J Forensic Med Toxicol.* 2020;14(4):8835-841.
- Swain SK, Behera IC, Mohanty S, Sahu MC. Rhinogenic contact point headache-Frequently missed clinical entity. *Apollo Med.* 2016;13(3):169-73.
- Herzallah IR, Hamed MA, Salem SM, Suurna MV. Mucosal contact points and paranasal sinus pneumatization: does radiology predict headache causality? *Laryngoscope.* 2015;125:2021-6.
- Abu-Bakra M, Jones NS. Does stimulation of the nasal mucosa cause refer pain to the face? *Clin Otolaryngol Allied Sci.* 2001;26:403-32.
- Swain SK, Das A, Samal R, Behera IC, Sahu MC. An unusually giant frontoethmoidal mucopyocele in a child-A case report. *Pediatrics Polska.* 2015;90(6):511-4.
- Tosun F, Gerek M, Ozkaptan Y. Nasal surgery for contact point headaches. *Headache.* 2000;40(3):237-40.
- Patel ZM, Kennedy DW, Setzen M, Poetker DM, DelGaudio JM. "sinus headache": rhinogenic headache or migraine? An evidence-based guide to diagnosis and treatment. *Int Forum Allergy Rhinol.* 2013;3(3):221-30.

12. Roe JO. The frequent dependence of persisted and so-called congestive headaches upon abnormal conditions of the nasal passages. *Med Record.* 1888;34:200-4.
13. Kunachak S. Middle turbinate lateralization: a simple treatment for rhinologic headache. *Laryngoscope.* 2002;112(5):870-2.
14. Peric A, Baletic N, Sotirovic J. A case of an uncommon anatomic variation of the middle turbinate associated with headache. *Acta Otorhinolaryngol Ital.* 2010;30(3):156-9.
15. Swain SK, Das A, Sahu MC. Anatomical variations of nose causing rhinogenic contact point headache-a study at a tertiary care hospital of eastern India. *Polish Ann Med.* 2018;25(1):51-5.
16. Swain SK, Dehta P, Pradhan S. Rhinoscleroma in a pediatric patient. *Apollo Med.* 2020;17(2):117-9.
17. Swain SK, Jena A, Sahu MC, Banerjee A. Eagle's Syndrome: Our experiences in a tertiary care teaching hospital of Eastern India. *J Head Neck Physicians Surgeons.* 2017;5(2):66-70.
18. Behin F, Behin B, Behin D, Baredes S. Surgical management of contact point headaches. *Headache.* 2005;45(3):204-10.
19. Lee HY, Kim CH, Kim JY, Kim JK, Song MH, Yang HJ et al. Surgical anatomy of the middle turbinate. *Clin Anatomy.* 2006;19(6):493-6.
20. Braun H, Stammberger H. Pneumatization of turbinates. *Laryngoscope.* 2003;113:668-72.
21. Stammberger H, Wolf G. Headaches and sinus disease: the endoscopic approach. *Ann Otol Rhinol Laryngol Suppl.* 1988;134:3-23.
22. Behin F, Lipton RB, Bigal M. Migraine and intranasal contact point headache: is there any connection? *Curr Pain Headache Rep.* 2006;10(4):312-5.
23. Swain SK, Sahu MC, Banerjee A. Non-sinonasal isolated facio-orbital mucormycosis—a case report. *J de mycol med.* 2018;28(3):538-41.
24. Gerbe RW, Fry TL, Fischer ND. Headache of nasal spur origin: an easily diagnosed and surgically correctable cause of facial pain. *Headache.* 1984;24:329-30.
25. Swain SK. Middle turbinate concha bullosa and its relationship with chronic sinusitis: a review. *Int J Otorhinolaryngol Head Neck Surg.* 2021;7(6):1062-67.
26. Swain SK, Behera IC, Sahu MC. Primary sinonasal tuberculosis: Our experiences in a tertiary care hospital of eastern India. *Egypt J Ear, Nose, Throat Allied Sci.* 2017;18(3):237-40.
27. Kalaiarasi R, Ramakrishnan V, Poyyamoli S. Anatomical variations of the middle turbinate concha bullosa and its relationship with chronic sinusitis: a prospective radiologic study. *Int arch otorhinolaryngol.* 2018;22:297-302.
28. Albirmawiy OA, Elsherif HS, Shehata EM, Younes A. Middle Turbinate Evacuation Conchoplasty in Management of Contact-Point Rhinogenic Headache in Children. *Int J Clin Pediatr.* 2010;1(4-5):115-23.
29. Sadeghi M, Saedi B, Ghaderi Y. Endoscopic management of contact point headache in patients resistant to medical treatment. *Indian J Otolaryngol Head Neck Surg.* 2013;65:415-20.
30. Swain SK, Sahu MC, Samantray K. An unusual cause of otalgia in a child-a case report. *Pediatr Pol.* 2016;91:480-3.
31. Mishra D, Choudhury KK, Gupta A. Headache with autonomic features in a child: cluster headache or contact-point headache? *Headache.* 2008;48:473-5.
32. Karatas D, Yuksel F, Senturk M, Dogan M. The contribution of computed tomography to nasal septoplasty. *J Craniofac Surg.* 2013;24:1549-51.
33. La Mantia I, Grillo C, Andaloro C. Rhinogenic contact point headache: surgical treatment versus medical treatment. *J Craniofac Surg.* 2018;29:228-30.
34. Eyigör H, Eyigör M, Erol B, Selçuk ÖT, Renda L, Yılmaz MD et al. Changes in substance P levels of inferior turbinate in patients with mucosal contact headache. *Brazilian j otorhinolaryngol.* 2020;86:450-5.
35. Peric A, Rasic D, Grgurevic U. Surgical treatment of rhinogenic contact point headache: an experience from a tertiary care hospital. *Int Arch Otorhinolaryngol.* 2016;20:166-71.
36. Kennedy DW, Zinreich SJ. The functional endoscopic approach to inflammatory sinus disease: Current perspectives and technique modifications. *Am J Rhinol.* 1988;2:89-96.
37. Har-el G, Slavut DH. Turbinoplasty for concha bullosa: a non-synechia-forming alternative to middle turbinectomy. *Rhinology.* 1996;34(1):54-6.
38. Huang HH, Lee TJ, Huang CC, Chang PH, Huang SF. Non-sinusitis-related rhinogenous headache: a ten-year experience. *Am J Otolaryngol.* 2008;29:326-32.
39. Chow JM. Rhinologic headaches. *Otolaryngol Head Neck Surg.* 1994;111:211-8.
40. Parsons DS, Batra PS. Functional endoscopic sinus surgical outcomes for contact point headaches. *Laryngoscope.* 1998;108:696-702.

**Cite this article as:** Swain SK, Baliarsingh P. Rhinogenic contact point headache in pediatric age group: a review. *Int J Contemp Pediatr* 2022;9:135-9.